

# Myocardial Edema Revisited in a New Paradigm of Cardiac Electrical Microcurrent Application in Heart Failure

Jesus Eduardo Rame, MD, MPhil,<sup>1</sup> and Johannes Müller, MD, MEng<sup>2,i</sup>

## Abstract

Undisturbed bioelectricity is a prerequisite for normal organ function. This is especially true for organs with high electrical activity such as the heart and the nervous system. Under clinical conditions, however, this can hardly be determined in patients with disturbed organ function and is therefore largely ignored. Here, based on clinical data, we will discuss whether the direct application of an external electric current (in the physiological  $\mu\text{A}$  range) together with an electrical field to hearts with impaired pump function can explain the functional improvement of the hearts by edema reduction triggered by electro-osmosis.

**Keywords:** cardiac microcurrent, myocardial edema reduction, electro-osmosis

## Highlights

- 1: Myocardial edema is a phenomenon accompanying many cardiovascular diseases, leading to progressive limitation of cardiac function in acute and chronic syndromes.
- 2: Therapeutic options to reduce myocardial edema and in turn impact myocardial function have not been described.
- 3: Application of electrical microcurrent directly to the heart has been demonstrated to improve myocardial function.
- 4: This observation could be explained by reduction of myocardial edema with the application of microcurrent and the effects of electro-osmosis.

**T**HE APPLICATION OF an electrical nonpulsating microcurrent to the heart of patients with moderate ambulatory New York Heart Association (NYHA) Class III heart failure can result in a rapid improvement in cardiac performance. A recently reported longitudinal study identified an increased left ventricular ejection fraction with a reduction in end-systolic and end-diastolic left ventricular size along with an increase in 6-min walk, NYHA functional class, and quality of life.<sup>1</sup>

There is a rapid functional improvement that can be demonstrated after only a few hours of microcurrent application (Fig. 1). If the early effects on the myocardium from

the application of a microcurrent are on this time scale (hours), we know that the attenuation of inflammation cannot explain the acute response being observed.<sup>2,3</sup> This short report proposes a mechanism of action for the early recovery of cardiac function that has been observed in the initial experience of microcurrent application.

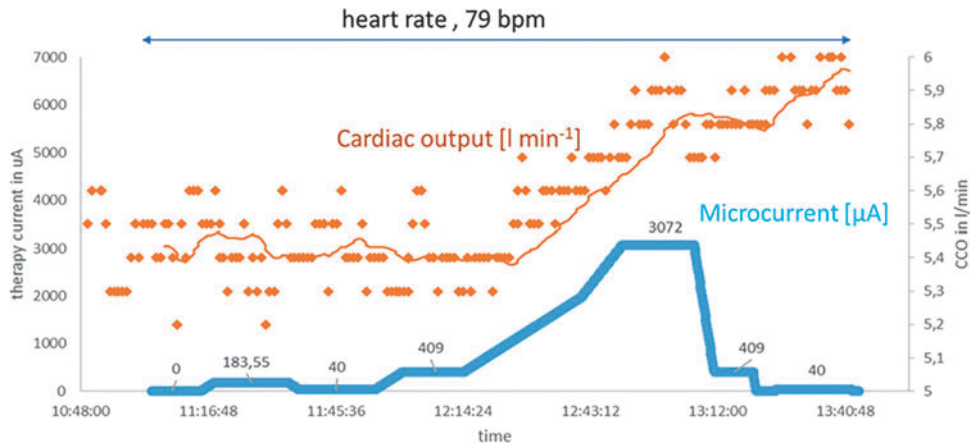
Although it receives little attention because of the lack of direct therapeutic interventional options and because its exact effect on the impairment of cardiac function is unknown, myocardial edema plays an essential role in the physiology of cardiac function and the pathology of heart failure.<sup>4-6</sup> Physical forces govern fluid filtration to a certain degree. Myocardial edema, the excess accumulation of fluid in the myocardial interstitium, develops when there is an imbalance between filtration from the coronary microvasculature, removal of interstitial fluid through lymphatic vessels, and epicardial transudation.<sup>7,8</sup> Under pathophysiological conditions, large quantities of proteins accumulate in the interstitial space, producing an osmotic/oncotic sucking force that drives fluid flow into the tissue and prevents fluid absorption back into the circulation. This chain of events creates the essential conditions for the formation of edema.<sup>9</sup>

Alteration of capillary permeability by inflammation (capillary leakage), loss of charge of the highly negatively charged glycocalyx, the inability of lymphatic system to drain the increased fluid, or a combination of these factors

<sup>1</sup>Department of Medicine, Jefferson Heart Institute, Philadelphia, Pennsylvania, USA.

<sup>2</sup>Department of Bioelectricity and Medical Research, Berlin Heals, Berlin, Germany.

<sup>i</sup>ORCID ID (<https://orcid.org/0000-0003-1478-3117>).



**FIG. 1.** Proportionality of electrical current application and cardiac output. In a sheep model with surgically implanted electrodes and measuring cardiac output through a CCO monitoring system (Vigilance; Baxter Healthcare Corporation's Edwards Critical-Care Division), we demonstrate the time correlation of microcurrent application and cardiac output. In this model, an increase in microcurrent is paralleled by an increase in cardiac output. Given the immediate stroke volume response, a mechanism that could explain the impact of microcurrent on the myocardium is a reduction in myocardial fluid content. Consistent with this observation is that a reduction in microcurrent does not lead to an immediate drop in CCO because the process of fluid retention is subject to a physiological delay of reaccumulation of fluid into the myocardium. Blue line, electrical microcurrent; ochre yellow line, result of a moving average smoothing process of the individual measuring points with a  $n=25$ . CCO, continuous cardiac output.

leads to the formation of myocardial edema.<sup>10–14</sup> Myocardial edema impairs myocyte contractility and is responsible for systolic and diastolic dysfunction.<sup>15–17</sup> Experimental data suggest that when myocardial fluid content is increased by only a few percent, cardiac output can easily be compromised by >15%.<sup>15,18,19</sup> Recently, a murine model of increased coronary sinus pressure inducing myocardial edema demonstrated significant cardiac contractile dysfunction within 24 h and the subsequent development of epicardial inflammation and fibrosis in the left ventricle.<sup>20</sup> Postmortem data of patients who died from cardiovascular diseases show a 30% increase in heart weight for men and a 22% increase for women, largely because of myocardial edema.<sup>21,22</sup>

Patients have been known to experience massive myocardial edema during acute myocarditis, requiring immediate intervention with mechanical assist pumps.<sup>23–26</sup> Moreover, beyond acute inflammatory cardiomyopathies associated with severe myocardial edema, a number of other cardiac conditions predispose to interstitial edema in the myocardium. After myocardial infarction, myocardial edema remains detectable for as long as 6 months.<sup>27</sup> Untreated acute myocardial edema is at least partially responsible for early death after myocardial infarction.<sup>28,29</sup> Consequently, cardiac contractile (systolic) dysfunction is probably an important factor contributing to the insufficient cardiac lymphatic drainage observed after myocardial infarction.<sup>30</sup> Myocardial edema has been detected among patients with arrhythmias who require support with defibrillators.<sup>31</sup> Patients with diabetes are more likely to experience long-lasting myocardial edema after infarction than are patients without diabetes.<sup>32</sup> Pulmonary hypertension has been associated with myocardial edema in patients with impaired left ventricular function.<sup>33</sup> Across the spectrum of heart failure, patients with dilated cardiomyopathy and reduced ejection fraction (HFrEF), mid-range ejection fraction (HFmEF), as well as patients with preserved ejection fraction (HFpEF), can exhibit substantial degrees of interstitial edema in the heart.<sup>8,34–37</sup>

Furthermore, because of capillary leakage and overstressed lymphatic drainage, any type of myocardial or systemic inflammation, including SIRS and sepsis, can probably also be associated with various degrees of myocardial edema.<sup>38</sup> For adequate drainage of the interstitium and transport of lymph, the lymphatic vessels require normal pumping function of the heart within certain limits. Thus, impaired cardiac function contributes to impaired lymphatic flow and leads to myocardial edema.<sup>16,39</sup>

The fatal feature of myocardial edema formation is that it not only impedes the pumping function of the heart in a purely mechanical manner but also exerts a proinflammatory effect, induces fibrosis, stimulates exuberant collagen synthesis in the interstitium by upregulating transforming growth factor- $\beta$  and the pro-collagen type I and type III, resulting in increased collagen deposition.<sup>40,41</sup> In addition, there is evidence indicating that the excitation-contraction uncoupling induced by myocardial edema causes contractile dysfunction.<sup>17,42</sup> Experimental removal of edema leads to an immediate improvement in the contractility of the heart.<sup>30</sup>

Thus, a therapeutic strategy is needed to allow patients to escape the vicious circle of edema, inflammation, and fibrosis associated with the frequently observed decline in cardiac function. This strategy should improve lymphatic flow independent of capillary permeability (negatively charged glycocalyx) and pressure conditions (hydrostatic and colloid osmotic) in the capillaries and the interstitium.<sup>43</sup>

Electrorheology, electrokinetics, and, in particular, electrophoresis and electro-osmosis describe the transport mechanisms of fluids or charged particles, mechanisms that are induced by the application of an electrical field or a direct current, in which an electrical field is inherent. Electrophoresis is well known in medicine as a method of inducing the migration of charged colloidal particles or molecules suspended in a solution by means of an electrical field, with the intention of separating and analyzing them in turn. In addition, within a living organism electrophoresis plays a relevant role in the distribution of molecules.<sup>44,45</sup>

Although electro-osmosis is well known in biophysics and biology, it is hardly known in medicine. It describes the phenomenon of the movement of a liquid through a capillary vessel bearing a surface charge caused by an electrical field parallel to the surfaces of the vessel.<sup>34,46,47</sup> Electro-osmotic flow may occur through small-channel structures such as gap junctions, capillaries, cells, and cell membranes across a heterogenous group of tissues. In particular, electro-osmotic flow can be found in areas of high electrical activity.<sup>48–50</sup> In addition to the flow generated by pulsatile or osmotic and hydrostatic pressure differences, electrokinetic flow is a relevant transport mechanism in even the smallest lymphatic and blood vessels.<sup>51</sup> Thus, edema formation can be interpreted in part as a disturbed electrical environment generating a potential gradient in the myocardium. This environment includes the negatively charged intraluminal layer (glycocalyx) of the fluid exchange vessels; this layer controls the permeability of the capillary wall and, in turn, the fluid balance and pressure conditions in the interstitium.<sup>5,40,52</sup>

An externally applied weak electric current together with an electrical field can interrupt the vicious circle of edema formation and impaired cardiac performance. It normalizes the electrical environment with the consequence of increasing lymphatic flow by supporting the electrokinetically induced transport of electro-osmosis and electrophoresis and may also influence the charge of the glycocalyx.<sup>50</sup>

The velocity  $V_{EO}$  of the electro-osmotic flow in response to an electrical field can be described by the Helmholtz–Smoluchowski relation:

$$V_{EO} = \varepsilon \varepsilon_0 \zeta V / \eta,$$

where  $\varepsilon$  is the permittivity of the medium (blood and lymphatic fluid),  $\varepsilon_0$  the dielectric constant of vacuum,  $\zeta$  is the zeta-potential of the relevant particles in the fluid,  $V$  is the strength of the external applied electrical field, and  $\eta$  is the viscosity of the fluid (blood and lymphatic fluid). More details about this process have been previously published.<sup>53</sup>

From this mathematical description, one can roughly estimate the strength of the electrical field that must be applied to achieve a certain velocity of lymphatic drainage. It must be recognized that the applied electrical field is inhomogeneous and cannot always be perfectly aligned in parallel with the vessels. Interestingly, the direct proportionality between flow velocity and external electrical field allows the determination of flow velocity by field strength within certain limits (Fig. 1).

Future translational work using cardiac magnetic resonance imaging to quantitate the degree of myocardial edema will determine if there is a correlation between the cardiac improvement achieved and the degree of resolution of myocardial edema induced by the application of a microcurrent. These studies could have important implications in acute cardiomyopathy syndromes, where the ability to reduce interstitial edema in the myocardium may promote cardiac recovery and prevent patients from progressive heart failure into cardiogenic shock.<sup>25</sup>

Today's heart failure therapy with pulsatile devices does not allow to clearly predict whether a patient will profit from the implantation of such a device. Information on existing edema might be used to stratify patients before implantation of a microcurrent device. Patients without myocardial edema

will most likely not show a rapid increase in cardiac function immediately after the implantation; they must wait for the anti-inflammatory effect of long-term application of microcurrent on myocardial function.

Without prejudging clinical confirmation, one could hypothesize that the spectrum of patients with heart failure who benefit from the application of microcurrent directly to the heart may be largely independent of the cause of the disease, depending only on the extent of myocardial edema.

In conclusion, the early improvement in cardiac function after the application of a microcurrent directly to and around the heart could implicate favorable changes in myocardial edema, which heretofore has not been a clinical target in human heart failure.

#### Author Disclosure Statement

No competing financial interests exist.

#### Funding Information

No funding was received for this article.

#### References

1. Kosevic D, Wiedemann D, Vukovic P, et al. Cardio-microcurrent device for chronic heart failure: First-in-human clinical study. *ESC Heart Fail* 2021;8:962–970.
2. Macfelda K, Kapeller B, Holly A, et al. Bioelectrical signals improve cardiac function and modify gene expression of extracellular matrix components: Bioelectrical signals and heart failure. *ESC Heart Fail* 2017;4:291–300.
3. Lau E, Cao Q, Ng DCM, et al. A large dataset of protein dynamics in the mammalian heart proteome. *Sci Data* 2016;3:160015.
4. Miller AJ. The grossly invisible and generally ignored lymphatics of the mammalian heart. *Med Hypotheses* 2011;76:604–606.
5. Verbrugge FH, Bertrand PB, Willems E, et al. Global myocardial oedema in advanced decompensated heart failure. *Eur Heart J Cardiovasc Imaging* 2017;18:787–794.
6. Cross CE, Rieben PA, Salisbury PF. Influence of coronary perfusion and myocardial edema on pressure-volume diagram of left ventricle. *Am J Physiol Leg Content* 1961;201:102–108.
7. O'Melia MJ, Lund AW, Thomas SN. The biophysics of lymphatic transport: Engineering tools and immunological consequences. *iScience* 2019;22:28–43.
8. Mehlhorn U, Geissler HJ, Laine GA, et al. Myocardial fluid balance. *Eur J Cardiothorac Surg* 2001;20:1220–1230.
9. Yuan SY, Rigor RR. Regulation of endothelial barrier function. *Colloq Ser Integr Syst Physiol Mol Funct* 2011;3:1–146.
10. van den Berg BM, Vink H, Spaan JAE. The endothelial glycocalyx protects against myocardial edema. *Circ Res* 2003;92:592–594.
11. Klotz L, Norman S, Vieira JM, et al. Cardiac lymphatics are heterogeneous in origin and respond to injury. *Nature* 2015;522:62–67.
12. Bradham RR, Parker EF. The Cardiac Lymphatics. *Ann Thorac Surg* 1973;15:526–528.
13. Brakenhielm E, González A, Díez J. Role of cardiac lymphatics in myocardial edema and fibrosis. *J Am Coll Cardiol* 2020;76:735–744.

14. Reitsma S, Slaaf DW, Vink H, et al. The endothelial glycocalyx: Composition, functions, and visualization. *Pflüg Arch Eur J Physiol* 2007;454:345–359.
15. Dongaonkar RM, Stewart RH, Geissler HJ, et al. Myocardial microvascular permeability, interstitial oedema, and compromised cardiac function. *Cardiovasc Res* 2010;87:331–339.
16. Taira A, Morishita Y, Arikawa K, et al. Flow velocity of cardiac lymph and contractility of the heart: An experimental study. *Ann Thorac Surg* 1977;23:230–234.
17. Desai KV, Laine GA, Stewart RH, et al. Mechanics of the left ventricular myocardial interstitium: Effects of acute and chronic myocardial edema. *Am J Physiol Heart Circ Physiol* 2008;294:H2428–H2434.
18. Dongaonkar RM, Stewart RH, Quick CM, et al. Award article: Microcirculatory society award for excellence in lymphatic ResearchTime course of myocardial interstitial edema resolution and associated left ventricular dysfunction: Myocardial edema resolution. *Microcirculation* 2012;19:714–722.
19. Ciutac AM, Dawson D. The role of inflammation in stress cardiomyopathy. *Trends Cardiovasc Med* 2021;31:225–230.
20. Nielsen NR, Rangarajan KV, Mao L, et al. A murine model of increased coronary sinus pressure induces myocardial edema with cardiac lymphatic dilation and fibrosis. *Am J Physiol Heart Circ Physiol* 2020;318:H895–H907.
21. Zagrosek A, Wassmuth R, Abdel-Aty H, et al. Relation between myocardial edema and myocardial mass during the acute and convalescent phase of myocarditis—A CMR study. *J Cardiovasc Magn Reson* 2008;10:19.
22. Kumar NT, Liestøl K, Løberg EM, et al. Postmortem heart weight: Relation to body size and effects of cardiovascular disease and cancer. *Cardiovasc Pathol* 2014;23:5–11.
23. Cooper LT. Myocarditis. *N Engl J Med* 2009;360:1526–1538.
24. Roberts WC, Kietzman AT. Severe eosinophilic myocarditis in the portion of left ventricular wall excised to insert a left ventricular assist device for severe heart failure. *Am J Cardiol* 2020;125:264–269.
25. Tschöpe C, Ammirati E, Bozkurt B, et al. Myocarditis and inflammatory cardiomyopathy: Current evidence and future directions. *Nat Rev Cardiol* 2021;18:169–193.
26. Mayr A, Klug G, Feistritz HJ, et al. Myocardial edema in acute myocarditis: Relationship of T2 relaxometry and late enhancement burden by using dual-contrast turbo spin-echo MRI. *Int J Cardiovasc Imaging* 2017;33:1789–1794.
27. Dall'Armellina E, Karia N, Lindsay AC, et al. Dynamic changes of edema and late gadolinium enhancement after acute myocardial infarction and their relationship to functional recovery and salvage index. *Circ Cardiovasc Imaging* 2011;4:228–236.
28. Ruder TD, Ebert LC, Khattab AA, et al. Edema is a sign of early acute myocardial infarction on post-mortem magnetic resonance imaging. *Forensic Sci Med Pathol* 2013;9:501–505.
29. Fernández-Jiménez R, García-Prieto J, Sánchez-González J, et al. Pathophysiology underlying the bimodal edema phenomenon after myocardial ischemia/reperfusion. *J Am Coll Cardiol* 2015;66:816–828.
30. Henri O, Poueche C, Houssari M, et al. Selective stimulation of cardiac lymphangiogenesis reduces myocardial edema and fibrosis leading to improved cardiac function following myocardial infarction. *Circulation* 2016;133:1484–1497.
31. Migliore F, Zorzi A, Perazzolo Marra M, et al. Myocardial edema as a substrate of electrocardiographic abnormalities and life-threatening arrhythmias in reversible ventricular dysfunction of takotsubo cardiomyopathy: Imaging evidence, presumed mechanisms, and implications for therapy. *Heart Rhythm* 2015;12:1867–1877.
32. Zia MI, Ghugre NR, Connelly KA, et al. Diabetes is associated with increased and persistent myocardial edema in infarct segment post acute myocardial infarction. *J Cardiovasc Magn Reson* 2012;14(S1):P29, 1532-429X-14-S1-P29.
33. Davis KL, Mehlhorn U, Laine GA, et al. Myocardial edema, left ventricular function, and pulmonary hypertension. *J Appl Physiol Bethesda Md* 1985 1995;78:132–137.
34. Fischer K, Guensch DP, Artho M, et al. Myocardial edema in heart failure with preserved ejection fraction. 2017. Available from: <http://rgdoi.net/10.13140/RG.2.2.23163.41763> (accessed March 27, 2017).
35. Boyle A, Maurer MS, Sobotka PA. Myocellular and interstitial edema and circulating volume expansion as a cause of morbidity and mortality in heart failure. *J Card Fail* 2007;13:133–136.
36. Jeserich M, Föll D, Olschewski M, et al. Evidence of myocardial edema in patients with nonischemic dilated cardiomyopathy. *Clin Cardiol* 2012;35:371–376.
37. Cuijpers I, Simmonds SJ, van Bilsen M, et al. Microvascular and lymphatic dysfunction in HFpEF and its associated comorbidities. *Basic Res Cardiol* 2020;115:39.
38. Vasques-Nóvoa F, Laundos TL, Madureira A, et al. Myocardial edema: An overlooked mechanism of septic cardiomyopathy? *Shock* 2020;53:616–619.
39. Misra JC, Pandey SK. Peristaltic transport of blood in small vessels: Study of a mathematical model. *Comput Math Appl* 2002;43:1183–1193.
40. Davis KL, Laine GA, Geissler HJ, et al. Effects of myocardial edema on the development of myocardial interstitial fibrosis. *Microcirculation* 2000;7:269–280.
41. Brakenhielm E, Alitalo K. Cardiac lymphatics in health and disease. *Nat Rev Cardiol* 2019;16:56–68.
42. Li G-R, Zhang M, Satin LS, et al. Biphasic effects of cell volume on excitation-contraction coupling in rabbit ventricular myocytes. *Am J Physiol Heart Circ Physiol* 2002;282:H1270–H1277.
43. Cui Y. The role of lymphatic vessels in the heart. *Pathophysiology* 2010;17:307–314.
44. Allen GM, Mogilner A, Theriot JA. Electrophoresis of cellular membrane components creates the directional cue guiding keratocyte galvanotaxis. *Curr Biol* 2013;23:560–568.
45. Jaffe LF. Electrophoresis along cell membranes. *Nature* 1977;265:600–602.
46. McLaughlin S, Poo MM. The role of electro-osmosis in the electric-field-induced movement of charged macromolecules on the surfaces of cells. *Biophys J* 1981;34:85–93.
47. Wiley D, Fimbres Weihs G. Electroosmosis [Internet]. In: Drioli E, Giorno L, eds. *Encyclopedia of Membranes*. Berlin, Heidelberg: Springer Berlin Heidelberg, 2015: 1–3. Available from: [https://doi.org/10.1007/978-3-642-40872-4\\_2079-1](https://doi.org/10.1007/978-3-642-40872-4_2079-1)
48. Pietak A, Levin M. Exploring instructive physiological signaling with the bioelectric tissue simulation engine. *Front Bioeng Biotechnol* 2016;4:55. Available from: <http://journal.frontiersin.org/Article/10.3389/fbioe.2016.00055/abstract>

49. Andreev VP. Cytoplasmic electric fields and electroosmosis: Possible solution for the paradoxes of the intracellular transport of biomolecules. *PLoS One* 2013;8: e61884.
50. Fischbarg J, Hernandez JA, Rubashkin AA, et al. Epithelial fluid transport is due to electro-osmosis (80%), plus osmosis (20%). *J Membr Biol* 2017;250: 327–333.
51. Hussain S, Ali N. Electro-kinetically modulated peristaltic transport of multilayered power-law fluid in an axisymmetric tube. *Eur Phys J Plus* 2020;135:348.
52. Gotloib L, Shostak A, Galdi P, et al. Loss of microvascular negative charges accompanied by interstitial edema in septic rats' heart. *Circ Shock* 1992;36:45–56.
53. Lvovich VF. Impedance spectroscopy: Applications to electrochemical and dielectric phenomena [Internet]. Hoboken, NJ: John Wiley & Sons, Inc., 2012. Available from: <http://doi.wiley.com/10.1002/9781118164075>

Address correspondence to:  
*Johannes Müller, MD, MEng*

*Department of Bioelectricity and Medical Research  
Berlin Heals  
Knesebeckstrasse 59-61  
Berlin 10719  
Germany*

*E-mail: [jmueller@berlinheals.de](mailto:jmueller@berlinheals.de)*